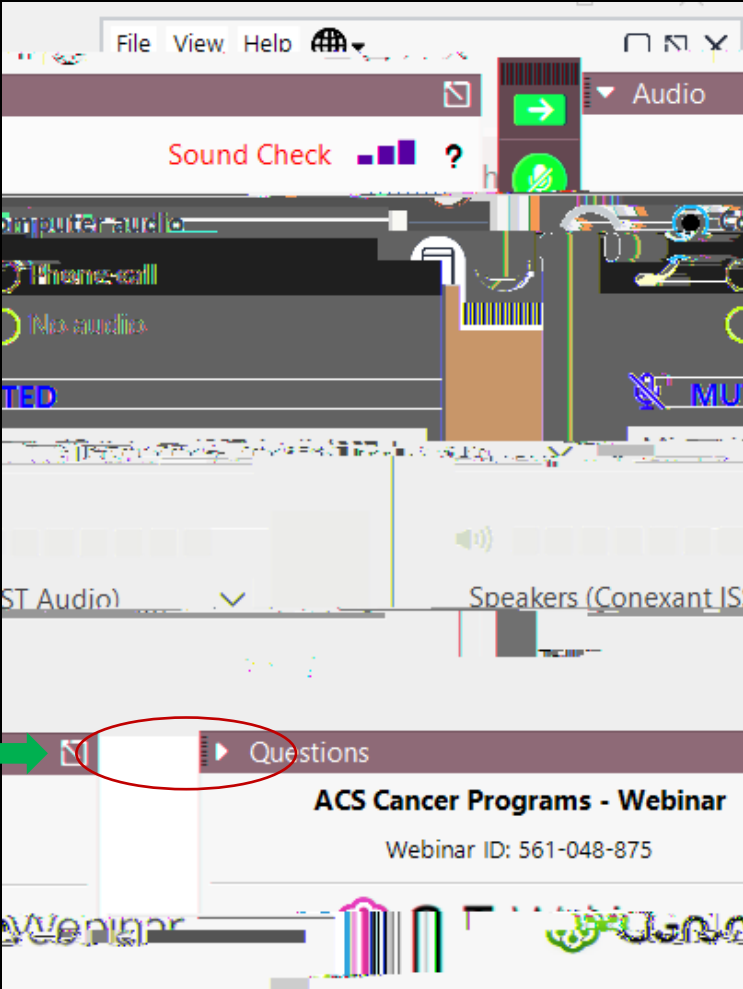


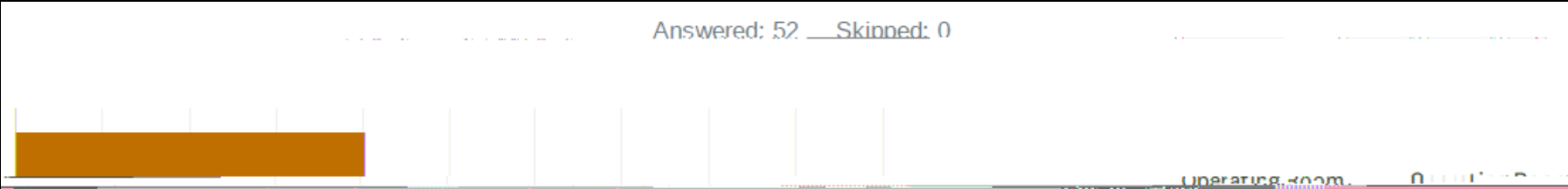
Standard 5.10 Photographs of Surgical Specimens: Challenges and Solutions with

Logistics

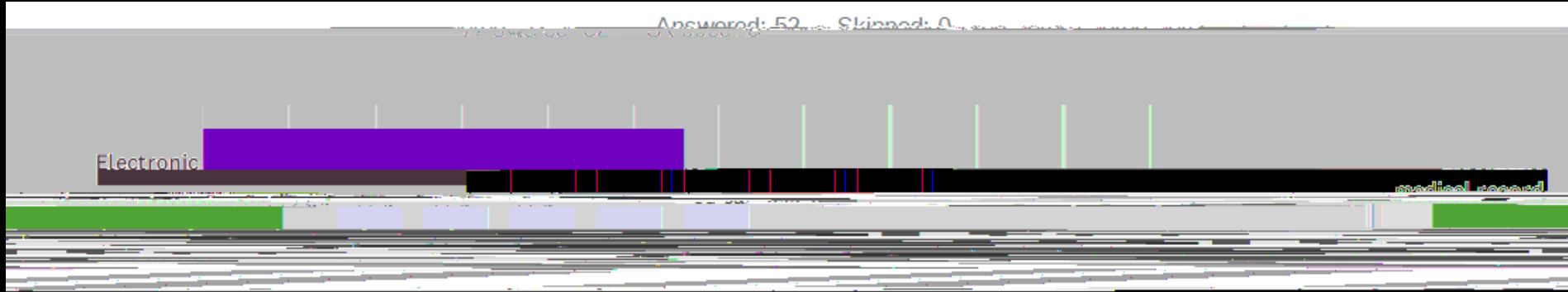



What is your NAPRC role?


Where are pictures of rectal cancer specimens being taken?




Where are the photos being uploaded?







Virginia Mason Franciscan Health




Standard 5.10 Photographs of Surgical Specimens: Challenges and Solutions Implementing the Standard

April 18th, 2023

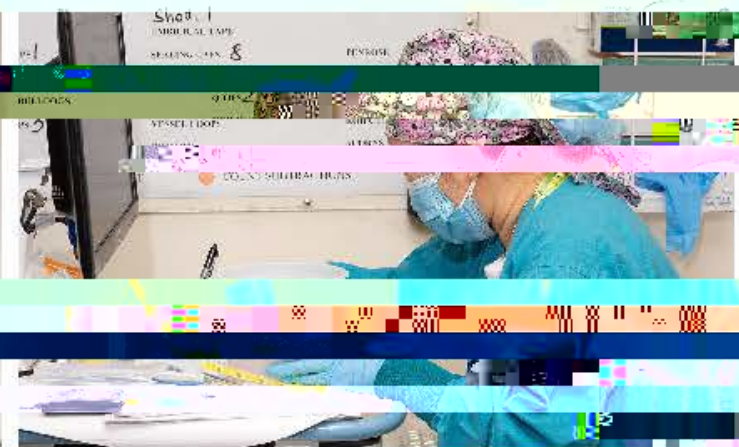
Operating room procedure for pathology

- Circulator / Surgeon confirm need for photograph
 - selectively → routinely for all colorectal specimens
- Specimen sent fresh/unopened to pathology





Operating Room Procedure for Pathology

- Circulator / Surgeon confirm need for medical photograph
 - selectively → routine for all colorectal specimens
- Specimen sent fresh/unopened to pathology



Meanwhile, in Pathology...





Tumor Board Pathology

- Anterior, posterior, and two lateral views presented with the Board presentation
- Grade 3, pT1c, N1c, M0 discussed

- Pathology discussion proceeds as normal

