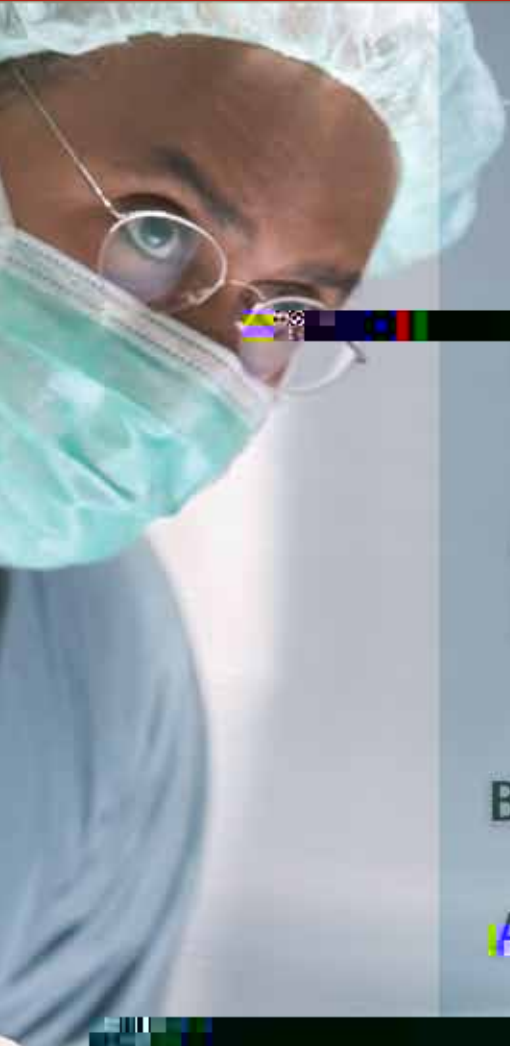



*Presidential
Address:*
**Achieving our
personal best**



**Back to the future
of the
American College
of Surgeons**



by
Andrew L. Warshaw, MD, FACS,
FRCSEd(Hon)






E P
 A D C
 n 2014 An C
 (AC) C C F , CA.




A n
 n
 E : L
 E : L n
 E : L n
 E : L
 P : P
 P : P n
 A n

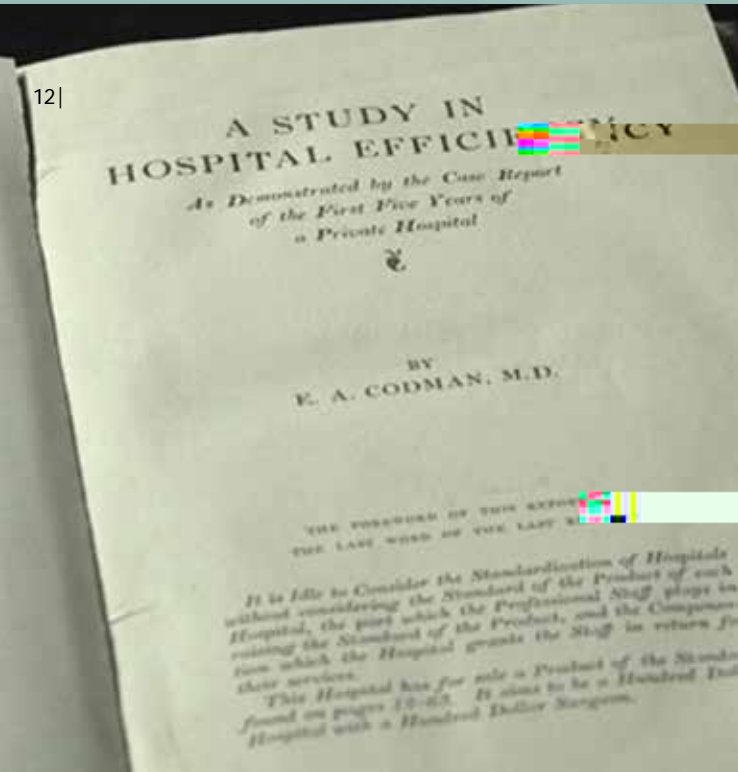
D . C n ' - n

Face of End Result Card


Name	Mr. Edward James Sullivan	Age	45	M. W. S.	Date of Adm.	Date of Discharge	Room No.
ADD. CITY	50 Gramercy Pl., New York City, N.Y.				5/2/14	7/7/14	204
Physician	Dr. C. M. Black, 46 Green St., Boston						
From	Mrs. George White, 124 St. John St., New York						
From the	Department of 						
From the	Address 						
Case by	Chief of 						
Diagnosis	No hematemesis, but some melena						
Operation	by C. A. Miller, W. C. Townsend & C. C. Calkins						
Remarks	Other and local anæsthesia. Operated by C. C. Calkins						
Path. No.	Sarcinæ, pigens, eggs on histological of stomach. Postul. gastroenteric						
Operation	Full bladder felt as if full of stones. Postoperative normal except for slight induration						
Remarks	of pylorus. Closed without drainage						
Operation	None. Except that drainage catheters be inserted several times without						
Remarks	apparent cause.						
Path. No.	Path. Report by J. A. Wright. Cause						
Signature	A. B. C.						

Reverse of End Result Card

Date	Remarks
July 11, '14	Remained well until March, 1912, since which time various symptoms returned, and also hematemesis and epigastric tumor.
Presently	July 11th. Epigastric tumor, numerous metastases in liver and all glands. No vom. Discharged to 




A Study in Hospital Efficiency D . C n



... a ...

... 1914 a ...
... 10 ...





22

Dr. Codman's legacy

(17)

6

1

6

1



REFERENCE

1.